

# Silver Sol Improves Wound Healing: Case Studies In the Use of Silver Sol in Closing Wounds (Including MRSA), Preventing Infection, Inflammation and Activating Stem Cells.

By

Gordon Pedersen Ph.D. and Keith Moeller

## Abstract

Wound healing is a complex and fragile process, which can be complicated by infection and inflammation. In this study, multiple cases are reviewed pictorially for the purpose of recording improved wound healing using the antimicrobial Silver Sol gel. The daily use of Silver Sol gel results in reduced infection (including MRSA), which leads to less inflammation. By reducing the inflammation and infection wounds close faster and with less scarring. This remarkable review of the healing process strongly suggests that Silver Sol gel helps disinfect the wound, prevents further infection, helps reduce inflammation and stimulates stem cells which results in improved wound healing characterized by reduced inflammation, improved angiogenesis, faster phagocytosis and reduced scarring.

Four cases were studied and evaluated for wound healing, infection control and stem cell activity, where the antimicrobial Silver Sol gel was used multiple times daily to help produce remarkable recoveries in; 1. A complicated MRSA infected wound. 2. Serious facial lacerations and the prevention of infection and inflammation. 3. A serious burn in an immune compromised patient. 4. A serious complicated (bollous pemphigoid) infection. These studies demonstrate improvements in healing outcomes sometimes in as little as half the normal healing time. The Silver Sol gel produced remarkable healing results in the MRSA infected wound by destroying the bacteria and helping to close a wound that was previously open and infected for over one year. Silver Sol gel helped produce a remarkable healing in a serious facial laceration preventing infection, significantly reducing inflammation resulting in an extremely rapid healing with little scarring. Silver sol gel was sprayed on a serious third degree burn in an 88 year old immune compromised patient helping to prevent infection and close a very difficult burn wound in two months. A bollous pemphigoid wound demonstrated re-epithelialization and stem cell function in closing a very serious wound.

## Literature Review

### Silver Sol and MRSA

Methicillin resistant staphylococcus aureus (MRSA) is approaching pandemic levels and there is an immediate need for a substance like Silver Sol in controlling this potentially

fatal disease. MRSA is a resistant variation of the common bacterium staphylococcus aureus. It is resistant to a significant group of antibiotics called the beta lactase, which include penicillins and cephalosporins (43). The organism is often sub-categorized as community associated MRSA (CA-MRSA) or health care associated MRSA (HA-MRSA). CA-MRSA cases were first reported in the late 1980's. Recently HA-MRSA has plagued the medical professionals and patients that work or live in hospitals. It is estimated that as much as 60% of Hospital nurses carry MRSA in their noses and on their skin (43). The CA-MRSA predominantly afflicts athletes, prisoners, nurses, soldiers, Native Americans, Native Alaskans, and children in inner cities (Wikipedia, 2008). MRSA could be considered to be a modern day plague because it has evolved the ability to survive treatment with most antibiotics including methycillin, dicloxocillin, nafcillin and oxacillin.

Hospitals have a special need for help in patients with open wounds that use invasive devices, or have a weakened immune system. These patients are at greater risk, which is also seen in the hospital employees who do not follow meticulous hygiene and proper sanitizing procedures. They may self-infect or transfer the contagion to patients or visitors. A study reported from the Association for Professionals in Infection Control and Epidemiology (2008), concluded that the poor hygiene habits remain the principle barrier to a significant reduction in the spread of MRSA. They also indicate that this hospital risk is exponentially great when you combine the propensity for the general public to spread this superbug in public restrooms, restaurants, airplanes, nurseries, schools, athletic events and in the home.

MRSA is progressing toward pandemic proportions. The Centers for Disease Control and Prevention (CDC), estimated that the number of MRSA infections doubled nationwide, from 127,000 in 1999, to 278,000 in 2005, while at the same time deaths increased from 11,000 to more than 17,000 (43). According to the Journal of the American Medical Association (JAMA Oct, 2007), MRSA was responsible for 94,360 serious infections and associated with 18,650 hospital stay related deaths in the United States in 2005. The statistics suggest that MRSA infections are responsible for more deaths in the U.S. each year than AIDS (44).

MRSA is growing out of control and the statistics suggest grave outcomes, but the level of seriousness is arguably misunderstood due to the fact that a study performed in San Francisco 2005, reported that approximately 1 in 300 residents suffered from MRSA. While during the course of the same year 85% of these infections occurred outside of the health care setting (45). A hospital study (46) reported that MRSA patients had, on average, three times longer stays (14.3 days vs. 4.5 days), incurred three times the expenditure (\$48,824 vs. \$14,141), and experienced five times the risk of in-hospital death (11.2% vs. 2.3%) as compared to patients without this infection (46). Wylie et al, reported a death rate of 34% within 30 days among patients infected with MRSA (47). The most common site of infection includes: The anterior nares (nostrils), respiratory tract, open wounds, intravenous catheters and urinary tract (47).

Hospitals in Denmark, Finland, Netherlands (49) and VA hospitals in Pittsburg (48) report that MRSA infections can be significantly reduced using sanitary methods that include swabbing the nostrils and hands with antibacterial protection. These studies demonstrate the potential benefits of an antibacterial agent prophylactically used on the hands and nostrils as long as resistance is not a potential long term problem.

MRSA is a resistant staphylococcus infection that usually presents as a patch of small pus surrounded by redness and swelling, and resemble pimples, spider bites, or boils that may not be accompanied by a fever and rash. The bumps become larger and spread where larger painful pus-filled boils can develop deep into the tissue (50). Approximately 75% of CA-MRSA infect the skin and whereas a minority of these infections can invade vital organs and cause sepsis, toxic shock syndrome, flesh eating (necrotizing) and pneumonia (51). It is not fully understood why some healthy people survive MRSA infections and others don't (51).

The current treatments of MRSA include Vancomycin and Teicoplanin, which are prescription antibiotics categorized as glycopeptides (52). The absorption of these antibiotics is very poor and must be given by intravenous administration to control systemic infections (53). There are several new strains of MRSA that have become resistant even to Vancomycin and Teicoplanin (54, 55). Presently the use of Linezolid, Quinupristin/Dalfopristin, Daptomycin and Tigecycline are used to treat more severe infections that do not respond to glycopeptides such as Vancomycin (56). In addition, oral treatments include Linezolid, Rifampicin + Fusidic acid, Rifampicin + Fluoroquinolone, Pristinamycin, Co-trimoxazole, Doxycycline or Minicycline and Clindamycin (67).

Nature (57) reported that there is a new drug which has demonstrated MRSA activity called Platensimycin (58, 59). It should be noted that some of the newest drug discoveries can cost \$1600 per day which may prohibit their ubiquitous distribution.

The spread of MRSA is complicated by the fact that hospitals discharge contagious patients into the community, workforce, schools, and general public (60). In the U.S. it is estimated that 95 million people carry staphylococcus aureus in their noses, of these 2.5 million carry MRSA (62), and 23% of these require hospitalization (63). MRSA is nearing pandemic proportions and there is a serious need for a daily use antibacterial that does not produce resistant strains of MRSA. Currently Silver Sol may be the only prophylactic use product that has activity against MRSA and could be used for prevention as well as treatment of MRSA because it does not produce resistant strains (66).

## **Normal Healing Processes**

The wound healing process is the body's natural process of repairing or regenerating dermal and epidermal tissue (skin). When the skin is wounded a set of complex biochemical events takes place in a closely orchestrated cascade to repair the damage (40.). These events take place simultaneously (2), and can be categorized into separate steps: The inflammatory, proliferative, and remodeling phases (1).

### **Inflammatory Phase:**

During the inflammatory phase clotting takes place, bacteria and debris are phagocytized and removed, while immune factors are released causing the activation, mobilization and division of cells involved in the proliferative phase.

When tissue is first wounded, blood comes in contact with collagen, triggering blood platelets to begin secreting inflammatory factors (9). Platelets also express glycoproteins on their cell membranes that allow them to stick to one another and to aggregate, forming a clot (4). Fibrin and fibronectin cross-link together and form a plug that traps proteins and particles and prevents further blood loss (10). This fibrin-fibronectin plug is also the main structural support for the wound until collagen is deposited (4). Migratory cells use this plug as a matrix to migrate across, and platelets adhere to it and secrete immune factors (4).

Platelets are the cells in highest numbers shortly after a wound occurs. They release ECM proteins, cytokines, growth factors and pro-inflammatory factors like serotonin, bradykinin, prostaglandins, prostacyclins, thromboxane and histamine (2). These serve a number of purposes including the mobilization, activation and proliferation of cells to the area of injury and cause blood vessels to become dilated and porous (2). Within an hour of wounding, polymorphonuclear neutrophils (PMNs) arrive at the wound site. Neutrophils phagocytise debris, and also kill bacteria by releasing free radicals in what is called a “respiratory burst” (14, 15). They also cleanse the wound by secreting proteases that break down damaged tissue. Neutrophils usually undergo apoptosis once they have completed their tasks and are engulfed and degraded by macrophages (16).

Other leukocytes to enter the area include helper T cells, which secrete cytokines to cause more T cells to divide and to increase inflammation and enhance vasodilation and vessel permeability (11, 17). T cells also increase the activity of macrophages (11). Macrophages are essential to wound healing (13). They replace PMNs as the predominant cells in the wound within two days after injury (18). Once they are in the wound site, monocytes mature into macrophages, the main cell type that clears the wound area of bacteria and debris (13). The macrophage's main role is to phagocytise bacteria and damaged tissue. It also debrides damaged tissue by releasing proteases. (20). Macrophages also secrete a number of factors such as growth factors and other cytokines, especially during the third and fourth post-wounding days. These factors attract cells involved in the proliferation stage of healing to the area (9).

Macrophages are stimulated by the low oxygen content of their surroundings to produce factors that induce and speed angiogenesis (14). And they also stimulate cells that re-epithelialize the wound, create granulation tissue, and lay down a new extracellular matrix (21, 22). Because they secrete these factors, macrophages are vital for pushing the wound healing process into the next phase.

Because inflammation plays roles in fighting infection and inducing the proliferation phase, it is a necessary part of healing. However, inflammation can lead to tissue

damage if it lasts too long (4). Thus the reduction of inflammation is frequently a goal in therapeutic settings. Inflammation lasts as long as there is debris in the wound. Thus the presence of bacteria, dirt or other objects can extend the inflammatory phase for too long, leading to a chronic wound.

As inflammation dies down, fewer inflammatory factors are secreted, existing ones are broken down, and numbers of neutrophils and macrophages are reduced at the wound site (13). These changes indicate that the inflammatory phase is ending and the proliferative phase is underway (13). Silver Sol helps to reduce the bacteria and foreign substances in the wound while stimulating the production of stem cells effectively shortening the inflammatory phase and accelerating the proliferative phase, which improves healing times.

### **Proliferative Phase:**

About two or three days after the wound occurs, fibroblasts begin to enter the wound site, marking the onset of the proliferative phase even before the inflammatory phase has ended (23). During the proliferative phase (also called the reconstruction phase), angiogenesis produces new blood vessels from endothelial cells (5), fibroblasts grow and form an extracellular matrix by excreting collagen and fibronectin (4), epithelial cells migrate across the wound bed to cover it. (6), and the wound is made smaller by the action of myofibroblasts which draw the edges of the wound together (4).

Because the activity of fibroblasts and epithelial cells requires oxygen, angiogenesis is imperative for other stages in wound healing, like epidermal and fibroblast migration (1). Angiogenesis is evident when the skin becomes red (erythematosis) due to the presence of capillaries (24).

In order to form new blood vessels and provide oxygen and nutrients to the healing tissue (25), stem cells called endothelial cells originating from parts of uninjured blood vessels develop pseudopodia and push through the ECM into the wound site. Through this activity, they establish new blood vessels (14).

To migrate, endothelial cells need collagenases and plasminogen activator to degrade the clot and part of the ECM (2, 13). Endothelial cells are also attracted to the wound area by fibronectin found on the fibrin scab and by growth factors released by other cells (25). Endothelial growth and proliferation is also stimulated by hypoxia and the presence of lactic acid in the wound (23). In a low-oxygen environment, macrophages and platelets produce angiogenic factors which attract endothelial cells chemotactically. When macrophages and other growth factor-producing cells are no longer in a hypoxic, lactic acid-filled environment, they stop producing angiogenic factors (14). Thus, when tissue is adequately perfused, migration and proliferation of endothelial cells is reduced.

By the end of the first week, fibroblasts are the main cells in the wound (2). Fibroplasia ends two to four weeks after wounding. Fibroblasts deposit ECM molecules like glycoproteins, glycosaminoglycans (GAGs), proteoglycans, elastin and fibronectin, which they can then use to migrate across the wound (Cohen, 2005).

Growth factors (PDGF, TGF-B) and fibronectin encourage proliferation, migration to the wound bed, and production of ECM molecules by fibroblasts. Fibroblasts also secrete growth factors that attract epithelial cells to the wound site. Hypoxia also contributes to fibroblast proliferation and excretion of growth factors, though too little oxygen will inhibit their growth and deposition of ECM components, and can lead to excessive, fibrotic scarring.

One of fibroblasts' most important duties is the production of collagen (24). Fibroblasts begin secreting appreciable collagen by the second or third post-wounding day (25), and its deposition peaks at one to three weeks (21). Collagen production continues rapidly for two to four weeks, after which its destruction matches its production and so its growth levels off (14).

Collagen deposition is important because it increases the strength of the wound.

Epithelialization is the formation of granulation tissue in an open wound and allows the cells to migrate across the new tissue to form a barrier between the wound and the environment (25). Basal keratinocytes from the wound edges and dermal appendages such as hair follicles, sweat glands and sebaceous (oil glands) are the main cells responsible for the epithelialization phase of wound healing (28). They advance in a sheet across the wound and proliferate at its edges, ceasing movement when they meet in the middle (28).

If the wound is very deep, skin appendages may also be ruined and migration can only occur from wound edges (30).

The more quickly this migration occurs, the less of a scar there will be (33).

Epithelial cells have the ability to phagocytize debris such as dead tissue and bacterial matter that would otherwise obstruct their path. Because they must dissolve any scab that forms, keratinocyte migration is best enhanced by a moist environment, since a dry one leads to formation of a bigger, tougher scab (20, 25, 28, 34). Keratinocytes also produce and secrete growth factors which aid both in epithelialization and in other phases of healing (36).

At first, contraction occurs without myofibroblast involvement (39). Later, fibroblasts, stimulated by growth factors, differentiate into myofibroblasts. Myofibroblasts are attracted by fibronectin and growth factors and they move along fibronectin linked to fibrin in the provisional ECM in order to reach the wound edges (20). They form connections to the ECM at the wound edges, and they attach to each other and to the wound edges by desmosomes. Also, at an adhesion called the fibronexus, actin in the myofibroblast is linked across the cell membrane to molecules in the extracellular matrix like fibronectin and collagen (39). Myofibroblasts have many such adhesions, which allow them to pull the ECM when they contract, reducing the wound size (38). In this part of contraction, closure occurs more quickly than in the first, myofibroblast-independent part (39).

As the actin in myofibroblasts contracts, the wound edges are pulled together. Fibroblasts lay down collagen to reinforce the wound as myofibroblasts contract (2).

Contraction occurs in order to reduce the size of the wound. A large wound can become 40 to 80% smaller after contraction (19, 28). Wounds can contract at a speed of up to 0.75 mm per day, depending on how loose the tissue in the wounded area is (25). Contraction usually does not occur symmetrically especially when the wound is dry, deep, contaminated or infected.

The contraction stage in proliferation ends as myofibroblasts stop contracting and commit apoptosis (38). The breakdown of the provisional matrix leads to a decrease in hyaluronic acid and an increase in chondroitin sulfate, which gradually triggers fibroblasts to stop migrating and proliferating (13). These events signal the onset of the maturation stage of wound healing.

Collagen deposition: before it is laid down, the only thing holding the wound closed is the fibrin-fibronectin clot, which does not provide much resistance to traumatic injury (14). Also, cells involved in inflammation, angiogenesis, and connective tissue construction attach to, grow and differentiate on the collagen matrix laid down by fibroblasts (27).

Even as fibroblasts are producing new collagen, collagenases and other factors degrade it. Shortly after wounding, synthesis exceeds degradation so collagen levels in the wound rise, but later production and degradation become equal so there is no net collagen gain. This homeostasis signals the onset of the maturation phase. Granulation gradually ceases and fibroblasts decrease in number in the wound once their work is done (28). At the end of the granulation phase, fibroblasts begin to commit apoptosis, converting granulation tissue from an environment rich in cells to one that consists mainly of collagen (2).

### **Remodeling and Maturation Phase:**

In the remodeling phase the wound matures. Collagen is remodeled and realigned along tension lines where the wound is contracting. During this process the cells that are no longer needed are removed by apoptosis. The healing process is complex, fragile and susceptible to interruption or failure which can lead to the formation of chronic non-healing wound. Some of the most significant factors which may contribute to the failure of a wound to heal, include; diabetes, venous or arterial disease, old age, and infection (7).

When the levels of collagen production and degradation equalize, the maturation phase of tissue repair is said to have begun (14). The maturation phase can last for a year or longer, depending on the size of the wound and whether it was initially closed or left open (21). During Maturation, type III collagen, which is prevalent during proliferation, is gradually degraded and the stronger type I collagen is laid down in its place (11). Originally disorganized collagen fibers are rearranged, cross-linked, and aligned along tension lines (19). As the phase progresses, tensile strength of the wound increases. The strength approaches 50% that of normal tissue by three months after injury and ultimately becomes as much as 80% as strong as normal tissue (21). Since activity at the wound site is reduced, the scar loses its erythematous appearance as blood cells that are no longer needed are removed by apoptosis (14).

The phases of wound healing normally progress in a predictable, timely manner; if they do not, healing may progress inappropriately to either a chronic wound (4) such as venous ulcers or pathological scarring such as a keloid scar (40, 41).

Silver Sol destroys bacteria, viruses and fungus, thus reducing the burden on the immune system and allowing an already overworked immune system to prioritize its actions towards healing and rebuilding functions. Stem cells are activated and work to improve healing outcomes.

## **Materials and Methods**

There are four case studies:

1. MRSA resolution and wound healing (Dr Shaw MD)
2. Silver Sol used to prevent infection and help improve wound healing.  
(G. Pedersen Ph.D.)
3. Burns, Infection control, wound healing and stem cells (G. Pedersen Ph.D.)
4. Stem cell activated infection bollous pemphigoid (Singapore)

The four case studies represent clinical manifestations using silver sol liquid and gel. All these case studies included giving the patients two teaspoons of liquid silver sol daily combined with twice daily application of silver sol gel. Silver Sol helped improve healing outcomes in all four of these case studies.

## **Case Study Results**

### **Case Study #1: Complicated MRSA Resolution & Wound Healing**

**Subject:** Female with infected mastectomy

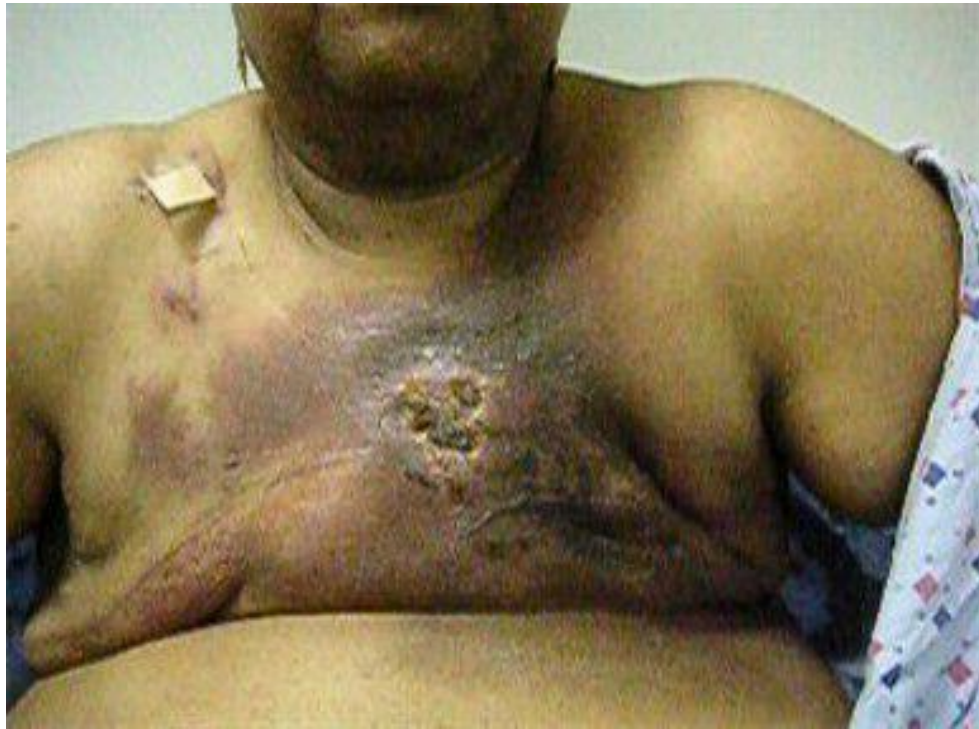**Wound:** Complicated MRSA Infection

**Treatment:** Silver Sol gel given topically 4 times a day.

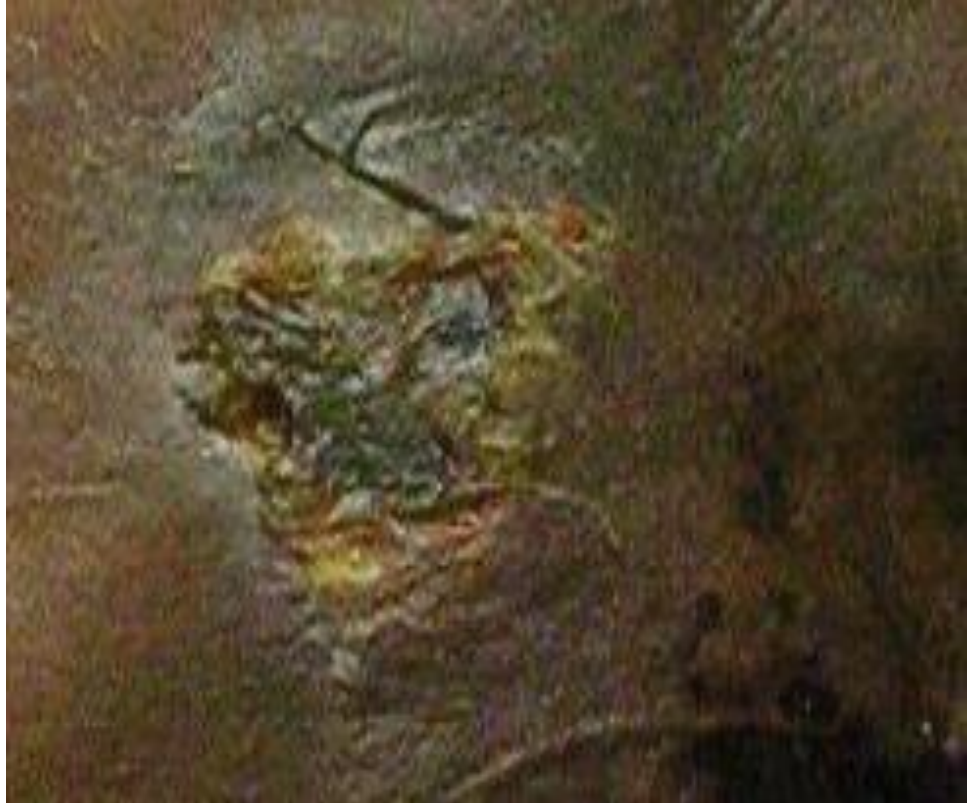**Results:** Photo series demonstrates complete resolution in five weeks.



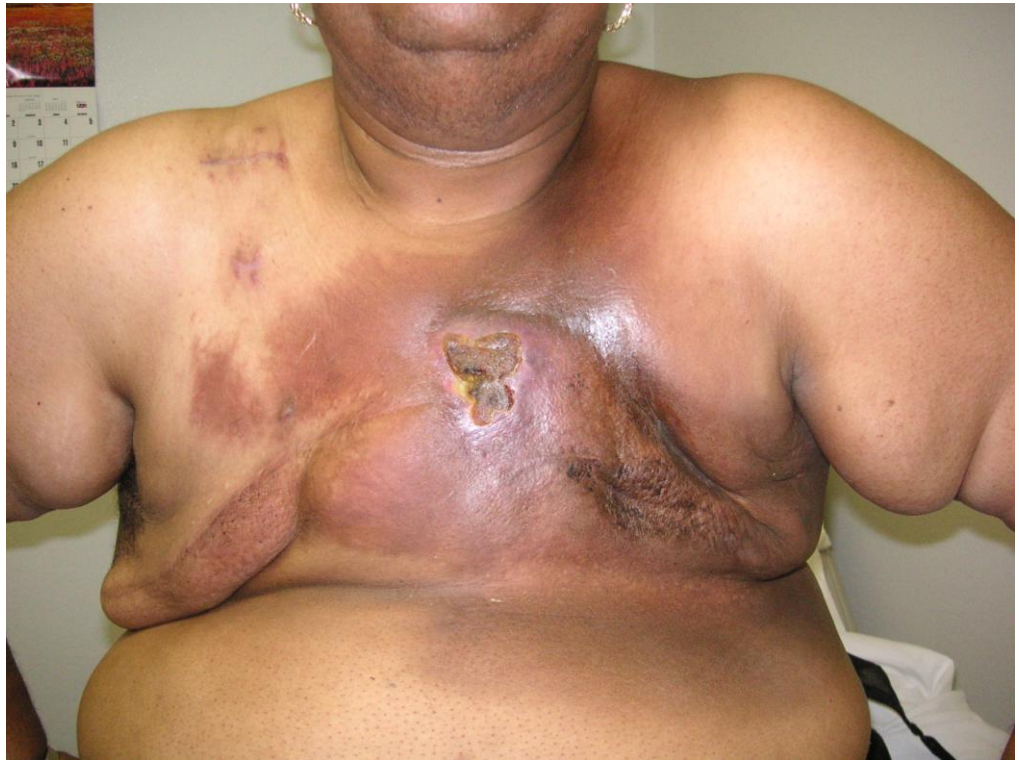**Day One:** MRSA infection ongoing one year.



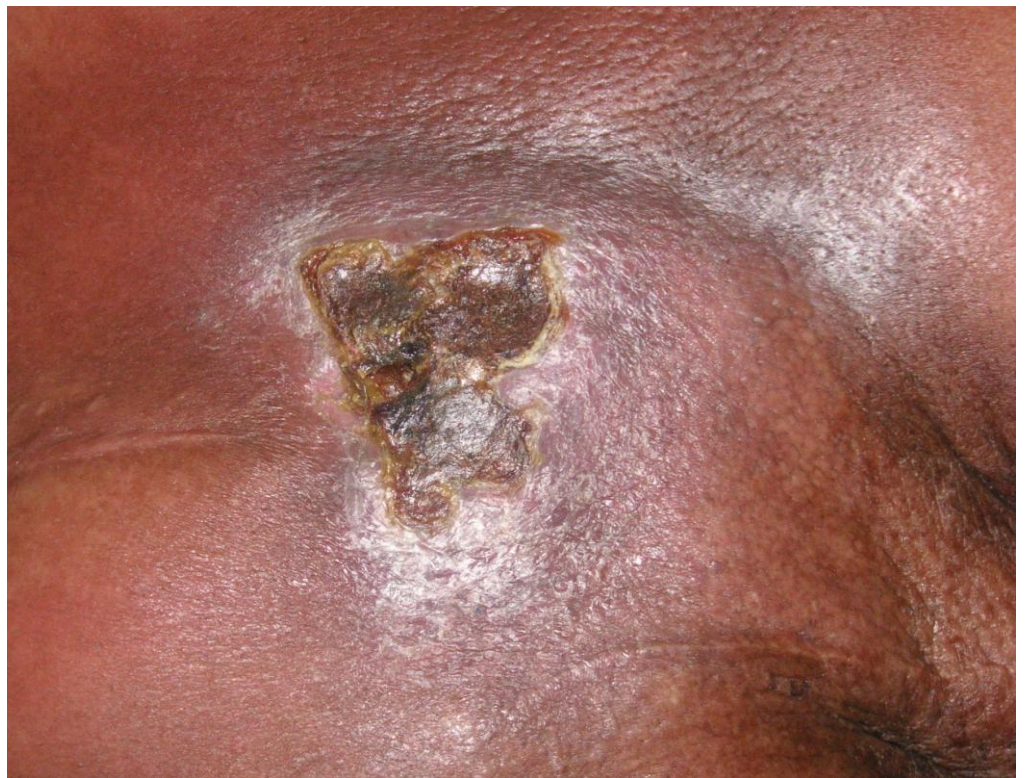**Close up** of tissues day one.



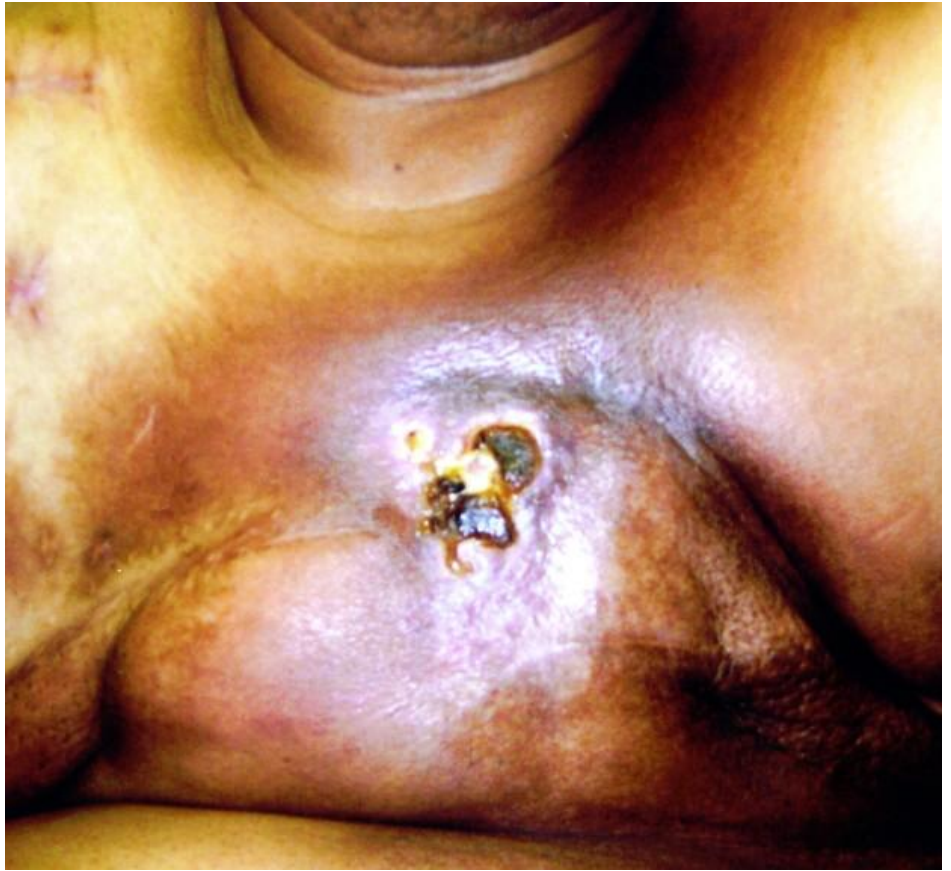**Day 17:** Significantly improved wound healing and reduction of MRSA



**Day 17:** Close up of tissues



**Day 21:** Wound totally closed and 95% healed, MRSA gone.



**Conclusion:** Silver Sol destroys HA-MRSA and promotes healing in a stubborn antibiotic resistant wound.

**Case Study #2: Silver Sol Used To Prevent Infection and Help Improve Wound Healing.**

**Subject:** A 47 year old male in good health.

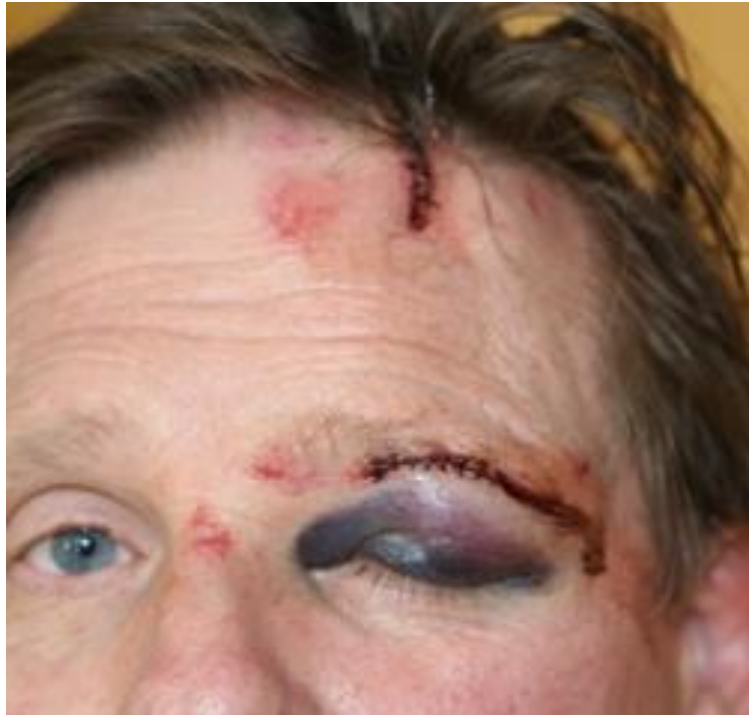**Wound:** Traumatic injury with serious laceration to the eye and forehead. 18 stitches over the eye and ten in the forehead were required to close the 2.5 inch long lacerations. The orbital bone was broken and a serious hematoma developed on both eyelids and the bridge of the nose.

**Treatment:** Silver Sol liquid given orally two teaspoons twice a day and silver sol gel given topically 4 times a day.

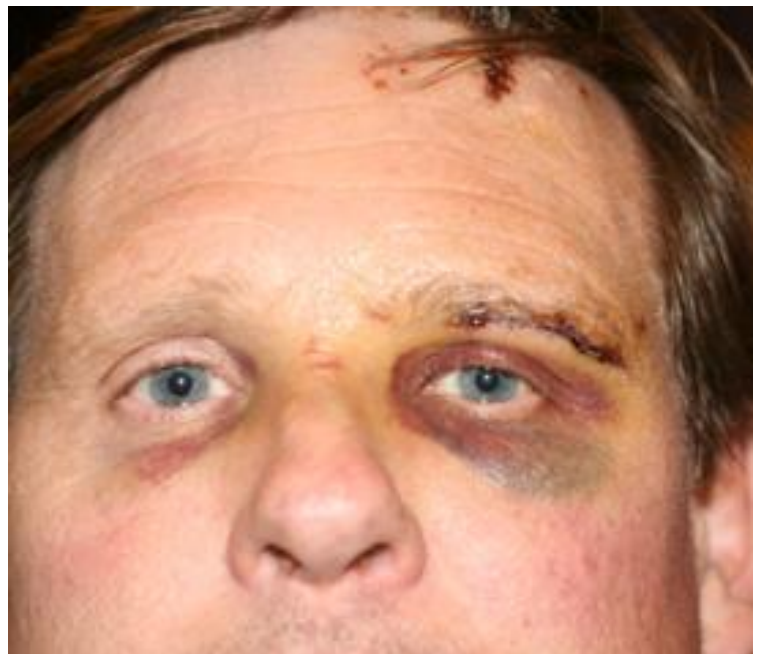**Results:** Photos were taken at the hospital immediately after suturing and every day thereafter. Complete healing by day 7.

**Day One:** Serious laceration and hematoma over left eye, broken orbital bone and laceration on left forehead at the hairline.

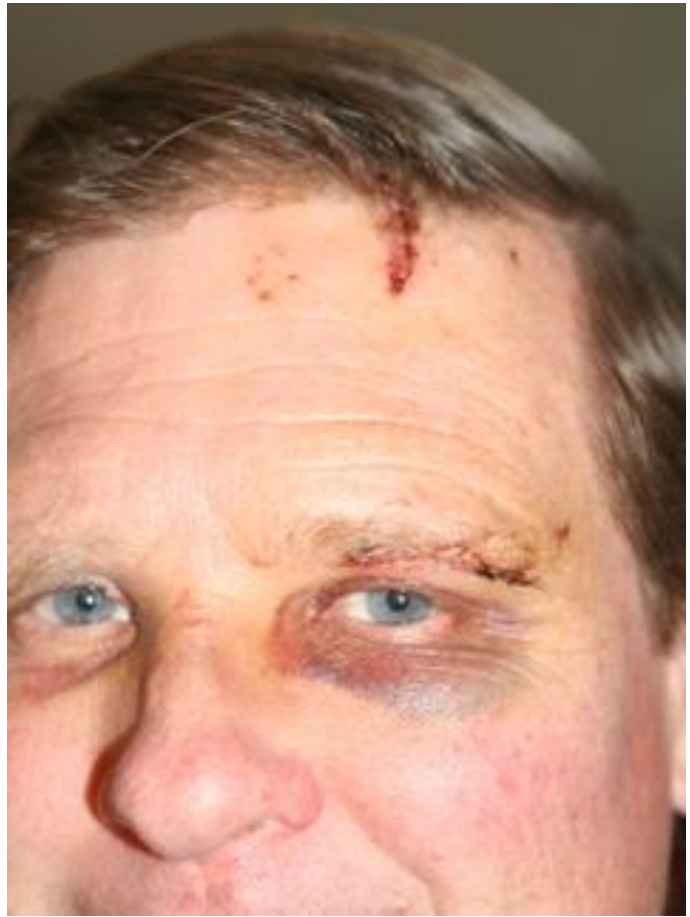Stitches were required to close the wounds.



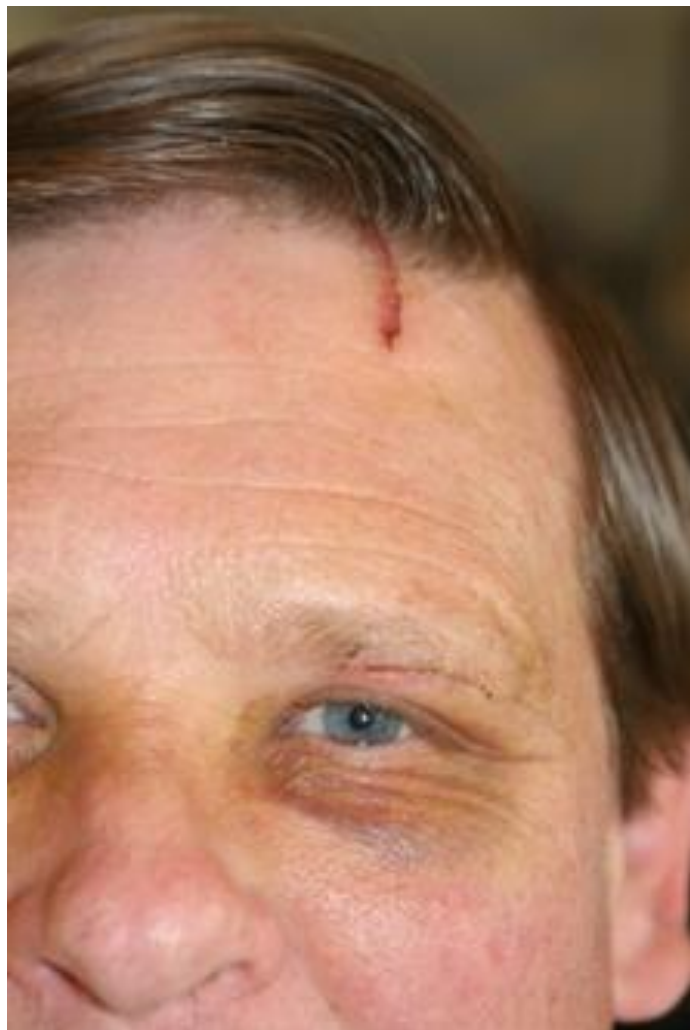**Day Two:** Bruise on left eye spreading around the eyes and bridge of nose.




**Day Three:** Stitches removed, bruising significant, no infection.



**Day Four:** Improved wound healing, inflammation reduced, and no infection.



**Day Six:** Wound healed,  
bruise nearly gone



**Day Seven:** Wound healed, bruise  
gone, inflammation gone, very little  
scar, no infection after 7 days.

Quote from Dr Al Molof (former  
President of Special Operations  
Medical Association) “It healed  
twice or maybe three times faster  
than any wound like it”.



## **Conclusions:**

The topical application of silver sol gel kills pathogens and helps protect the wound from becoming contaminated or infected which means that the inflammatory phase of wound healing received significant assistance possibly by reducing the need for macrophages, monocytes and fewer cytokines producing less inflammatory response hormones. The fact that there is less inflammation suggests that there is a significant reduction in the inflammatory phase of healing. Since the silver sol destroys bacteria, viruses and mold the wound was not infected thus reducing the need for phagocytosis, which reduces the immune cascade required for clotting and decontamination of the wound. The elimination of bacteria leaves the wound edges and margins clean and capable of optimal healing. In addition there is an increased ability to secrete stem cells, which will produce multi-potent cellular healing. This produces obstacle free wound healing making a cleaner healing scar. This can be seen in the fact that the wound was closed and stitches removed by day three where the wound presented a very low amount of inflammation, with no bacterial contamination. This could help explain why there is very little scarring. This could also be due to the fact that with less inflammation, there is less need for the platelets to produce histamine, cytokines and prostaglandins, which results in less overall swelling which means the wound can heal faster due to the fact that there are less factors competing with collagen. This reduced inflammation results in more collagen filling the fibrin - fibronectin matrix producing less tension, better bridging to migrate across the wound and less constriction (fibrotic scarring of the wound). In addition the gel provides a wound that is moist promoting the migration of polymorphonuclear cells stretching across the wound, which can lay the foundation of a healthy uncomplicated wound. In addition it appears that stem cell activation (as published in Nexus 2008), could be responsible for the rapid adhesion of the laceration and assist in the removal of the scab and reduction of the scarring. This could occur because the endothelialization had less opposition from bacteria, mold and inflammation. It appears that stem cells had activated and mobilized angiogenesis from the healthy blood vessels as evidenced by the pink coloration of the tissues immediately surrounding the suture lines which indicate that stem cell activated angiogenesis had taken place with remarkable results probably due to the fact that there was no bacterial infection nor any contamination and its associative inflammation.

In short the Silver Sol appears to play a significant role to decontaminate, prevent infection and stimulate stem cells resulting in improved wound healing characterized by reduced inflammation, improved angiogenesis, more efficient phagocytosis and reduced scarring.

Since there is less need for polymorphonuclear cells there will be less helper T cells secreting cytokines which cause the multiplication of inflammatory factors. This means there is less clean-up of inflammation and the wound in general. In addition there will be better stem cell production from the healthy fringes of the blood vessels, better collagen production and improved circulation due to the fact that vasodilation and blood vessel permeability will be normalized sooner in an uninfected and less inflamed wound. All of these parameters seem to have one thing in common; Silver Sol has antimicrobial abilities that help reduce infection, and inflammation resulting in better healing. Since inflammation lasts as long as there is debris or infection in the wound, it can be said that Silver Sol can help remove the cause of a significant amount of infection and inflammation. This results in improved healing outcomes by reducing the pathogenic burden on the immune system allowing optimal restorative and regenerative immune functions.

### **Case Study #3**

#### **Infection Control In a Serious Third Degree Burn.**

**Subject:** 88 year old woman

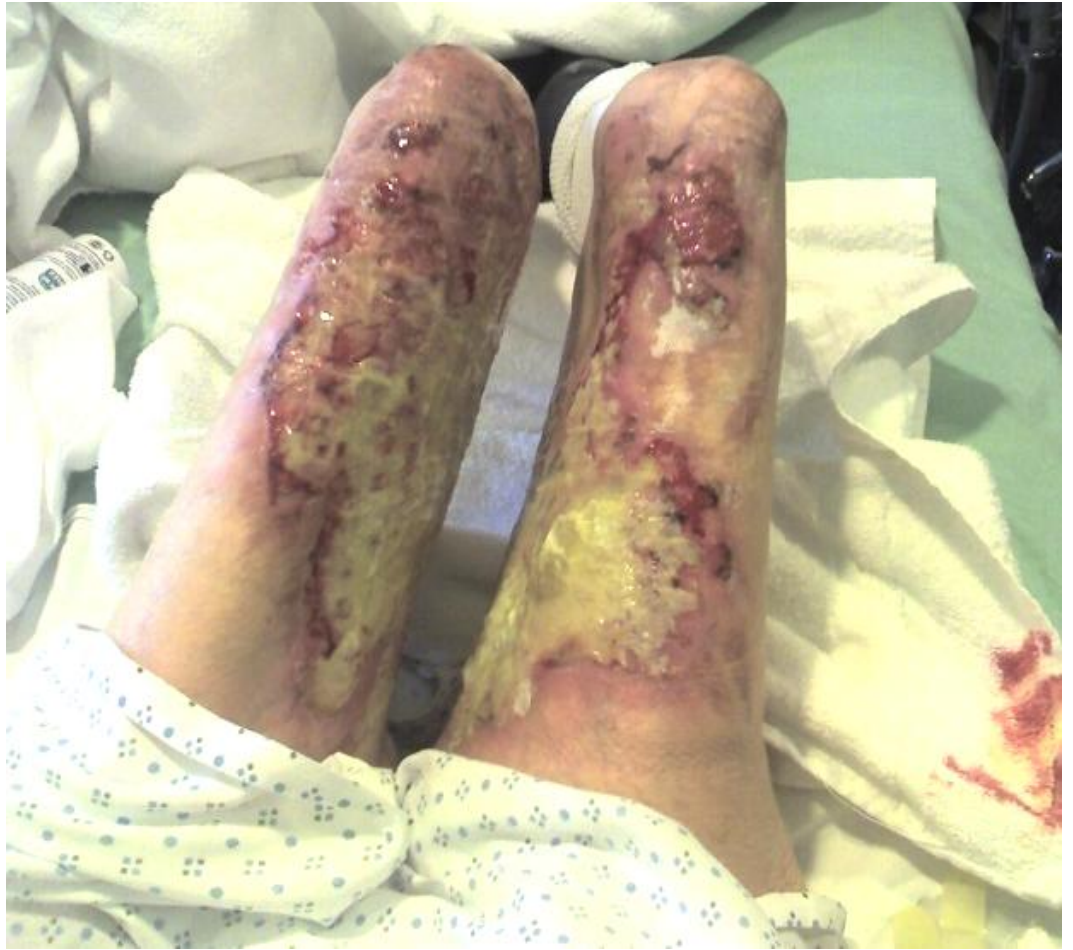**Wound:** Third degree burn over both thighs with potential pseudomas aeruginosa, and MRSA infections.

**Treatment:** Silver Sol gel sprayed on topically once a day when bandages were changed.

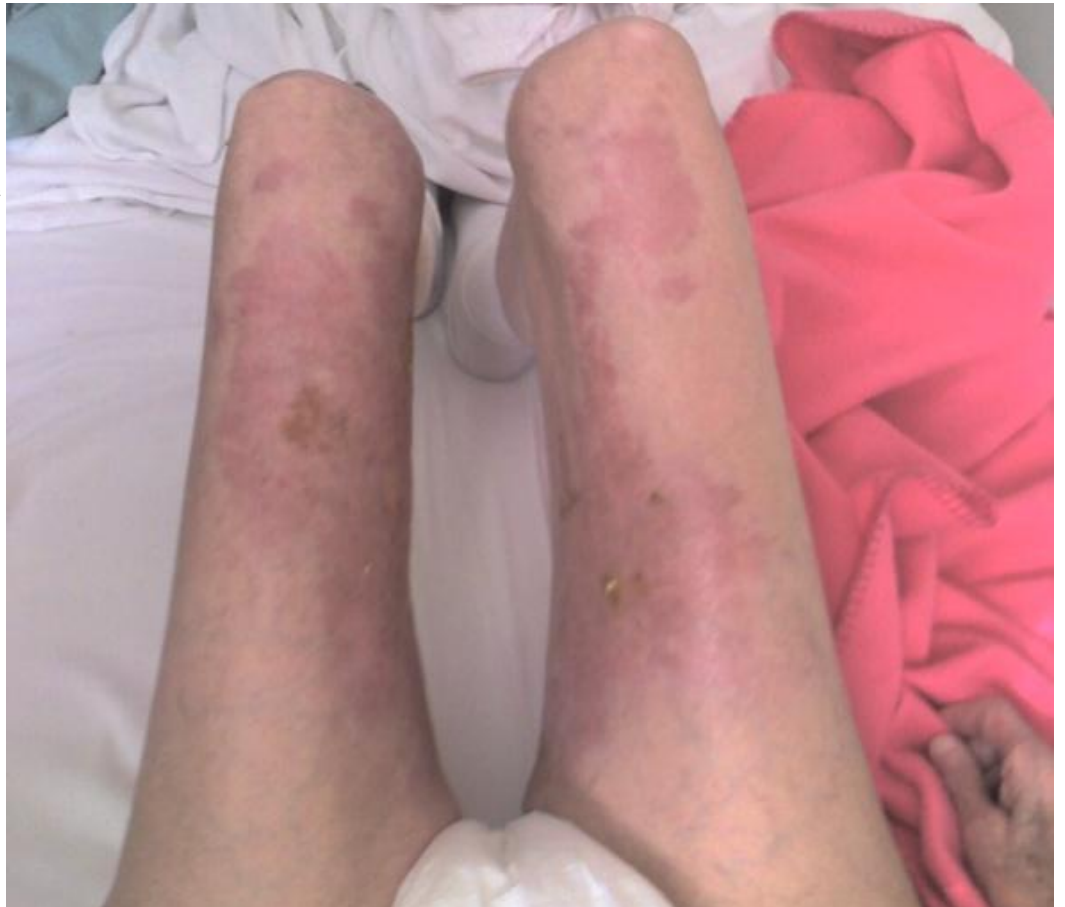**Results:** Photos illustrate total healing in 65 days.



**Day One:** Third Degree burn deep into the skin, adipose tissue and muscles. Subject was unable to receive skin grafts do to her age and compormized immunity.



**Day 65:** Complete healing with no infection. The wound is discolored but relatively scar-free after 65 days.



## **Conclusion:**

Silver Sol prevents infection in a very large and exposed area. A wound this size would normally require skin grafting, but with the activation of stem cells re-epithelialization can regenerate healthy tissue across the wound. Evidence suggests this is what has happened in this case.

## **Case Study #4**

### **Epithelialization of Wound With Bollous Pemphigoid.**

**Subject:** 48 year old male.

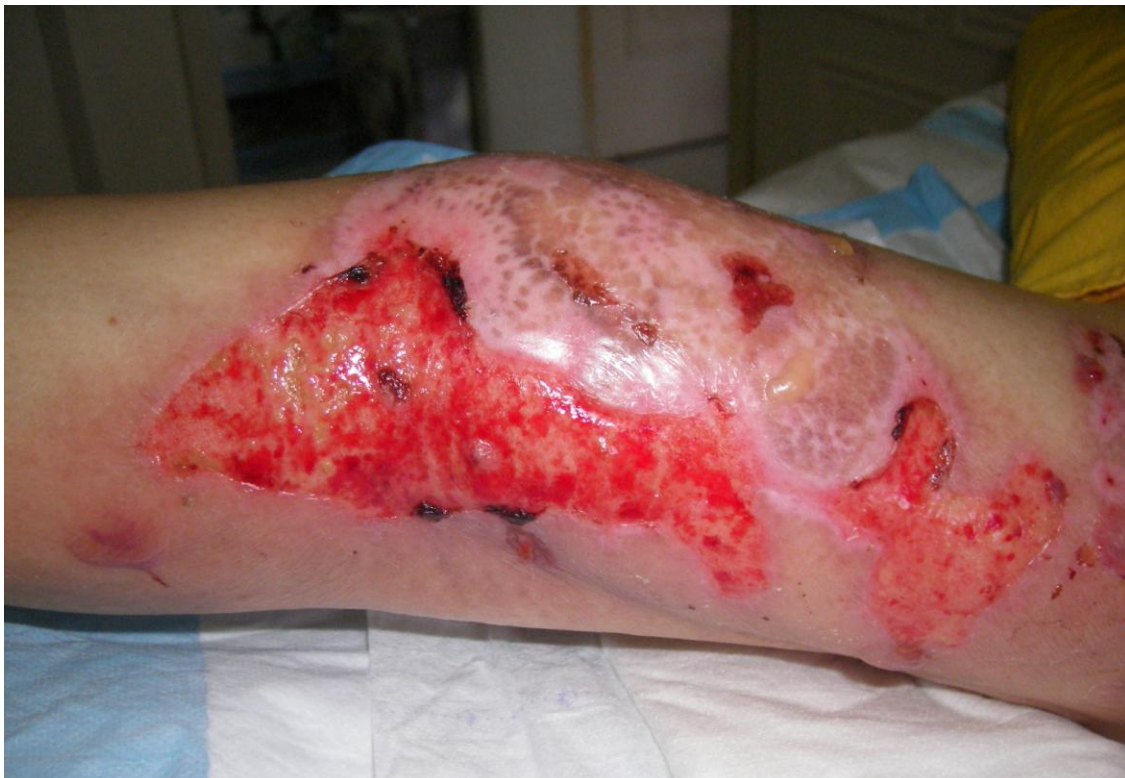**Wound:** MRSA infection with bollous pemphigoid (autoimmune) complication.

**Treatment:** Silver Sol liquid given orally two teaspoons twice a day and silver sol gel sprayed on topically once a day when bandages were changed.

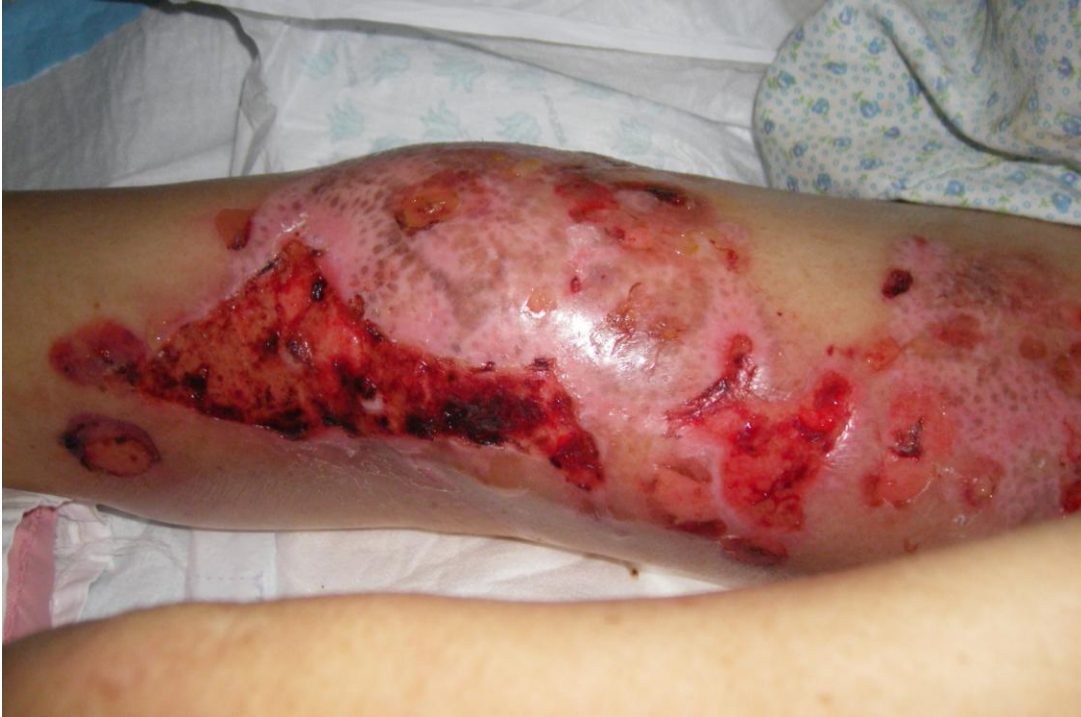**Results:** MRSA infection controlled, autoimmune attack on tissues controlled and epithelialization of wound helps heal and close the wound.

**Day One: Wound developed bollous pemphigoid (autoimmune)**

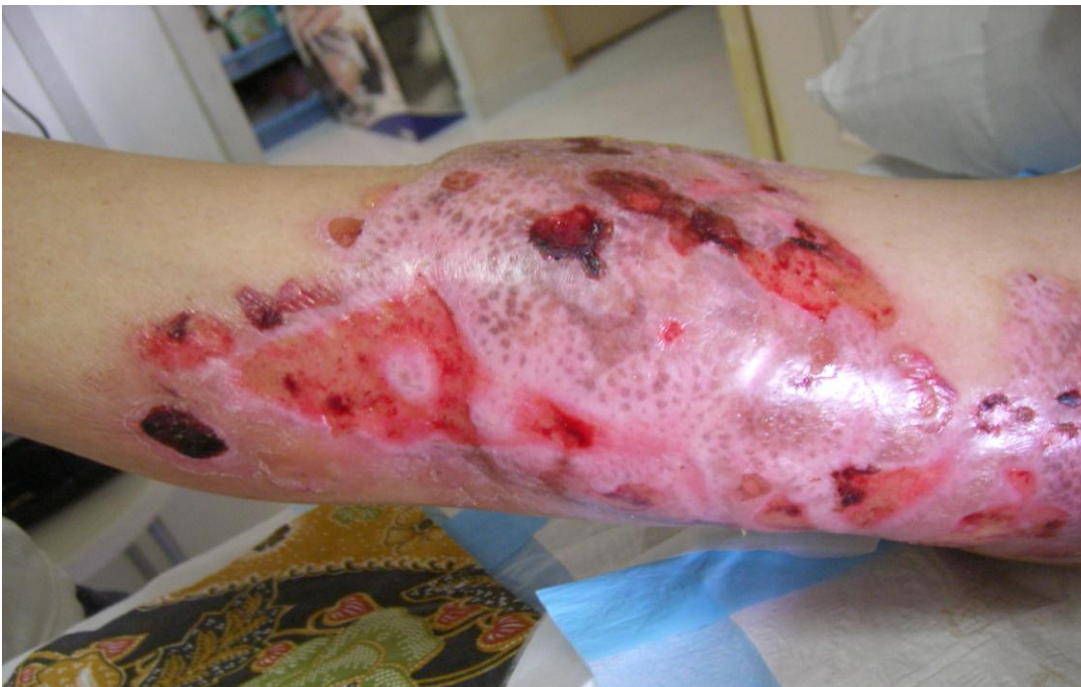**Before treatment with Silver Sol**



**Four days after Silver Sol treatment**



**Ten Days After Silver Sol Treatment. Note islands of epithelialization (indicating stem cell activity).**



## **Conclusions**

Silver Sol has the ability to keep the wound moist, control infection, help stimulate stem cells and improve the healing outcome in this serious autoimmune complication. The photographs illustrate how the wound is healing from the margins and concurrent stem cell activity in the center of the wound is producing epithelialization and tissue regeneration even in areas where the margins of the skin do not directly contact the open wound.

## **Summary**

The observations of these cases suggest that Silver Sol enhances healing outcomes through the following actions:

1. Destroys MRSA in human subjects.
2. Improves wound healing in ongoing serious HA-MRSA wounds.
3. Improves wound healing in serious third degree burns.
4. Controls infection in open wounds.
5. Improves wound healing times and reduces scarring in a serious laceration.
6. Silver Sol keeps the wound moist allowing greater cellular migration across the wound thus accelerating the closure of a wound and reduction of scarring.
7. Stem cell activation is present, as observed in the center of the wound (beyond the wound margins) where re-epithelialization produced improved healing. It is remarkable to have a serious autoimmune wound heal so quickly and may be due to the reduction in inflammation and improved immune function modulated through the use of Silver Sol gel.
8. Stem cell activation and production must have occurred as seen in the after photo which clearly illustrates discoloration of the scar but leaves no adverse scarring, pulling or adhesions on the surface of the wound. This is remarkable since most wounds of this nature would have required skin grafting to close the wound.

Silver Sol helps control unwanted bacteria, viruses and fungi which removes much of the workload from the immune system. This allows the immune components to perform their very specialized tasks without opposition while preventing secondary infection resulting in faster wound healing, with less scarring.

## References

1. Galko MJ, Krasnow MA (2004). "[Cellular and genetic analysis of wound healing in \*Drosophila Larvae\*](#)". *PLoS Biology* **2** (8): e239. doi:10.1371/journal.pbio.0020239.
2. Stadelmann W.K., Digenis A.G. and Tobin G.R. (1998). Physiology and healing dynamics of chronic cutaneous wounds. *The American Journal of Surgery* **176** (2): 26S-38S. PMID 9777970.
3. Quinn, J.V. (1998). *Tissue Adhesives in Wound Care*. Hamilton, Ont. B.C. Decker, Inc. Electronic book.
4. Midwood K.S., Williams L.V., and Schwarzbauer J.E. 2004. Tissue repair and the dynamics of the extracellular matrix. *The International Journal of Biochemistry & Cell Biology* **36** (6): 1031–1037. PMID 15094118.
5. Chang H.Y., Sneddon J.B., Alizadeh A.A., Sood R., West R.B., Montgomery K., Chi J.T., van de Rijn M, Botstein D., Brown P.O. (2004). [Gene Expression Signature of Fibroblast Serum Response Predicts Human Cancer Progression: Similarities between Tumors and Wounds](#). *Public Library of Science* **2** (2). PMID 14737219. Accessed January 20, 2008.
6. Garg, H.G. (2000). *Scarless Wound Healing*. New York Marcel Dekker, Inc. Electronic book.
7. Enoch, S. Price, P. (2004). *Cellular, molecular and biochemical differences in the pathophysiology of healing between acute wounds, chronic wounds and wounds in the elderly*. Worldwidewounds.com.
8. "[The Molecular Biology of Wound Healing](#)" (2004) **2** (8). doi:10.1371/journal.pbio.0020278.

9. Rosenberg L., de la Torre J. (2006). [Wound Healing, Growth Factors](#). Emedicine.com. Accessed [January 20, 2008](#).
10. Sandeman S.R., Allen M.C., Liu C., Faragher R.G.A., Lloyd A.W. (2000). Human keratocyte migration into collagen gels declines with in vitro ageing. *Mechanisms of Ageing and Development* **119** (3): 149-157. [PMID 11080534](#).
11. Dealey C. (1999). *The care of wounds: A guide for nurses*. Oxford ; Malden, Mass. Blackwell Science. Electronic book.
12. Theoret C.L. (2004). Update on wound repair. *Clinical Techniques in Equine Practice* **3** (2): 110-122.
13. De la Torre J., Sholar A. (2006). [Wound healing: Chronic wounds](#). Emedicine.com. Accessed [January 20, 2008](#).
14. Greenhalgh D.G. (1998). The role of apoptosis in wound healing. *The International Journal of Biochemistry & Cell Biology* **30** (9): 1019–1030. [PMID 9785465](#).
15. Muller M.J. , Hollyoak M.A., Moaveni Z., La T., Brown H., Herndon D.N., Heggers J.P. 2003. Retardation of wound healing by silver sulfadiazine is reversed by Aloe vera and nystatin. *Burns* **29** (8): 834-836. [PMID 14636760](#).
16. Martin P. and Leibovich. (2005). Inflammatory cells during wound repair: the good, the bad and the ugly. *Trends in Cell Biology* **15** (11): 599-607. [PMID 16202600](#).
17. Santoro M.M. and Gaudino G. (2005). Cellular and molecular facets of keratinocyte reepithelization during wound healing. *Experimental Cell Research* **304** (1): 274-286. [PMID 15707592](#).
18. Expert Reviews in Molecular Medicine. (2003). [The phases of cutaneous wound healing](#). **5**: 1. Cambridge University Press. Accessed [January 20, 2008](#).
19. Lorenz H.P. and Longaker M.T. (2003). [Wounds: Biology, Pathology, and Management](#). Stanford University Medical Center. Accessed [January 20, 2008](#).
20. Deodhar A.K., Rana R.E. (1997). [Surgical physiology of wound healing: a review](#).

- Journal of Postgraduate Medicine* **43** (2): 52-56. PMID 10740722. Accessed January 20, 2008.
21. Mercandetti M., Cohen A.J. (2005). [Wound Healing: Healing and Repair](#). Emedicine.com. Accessed January 20, 2008.
  22. Stashak T.S., Farstvedt E., Othic A. (2004). Update on wound dressings: Indications and best use. *Clinical Techniques in Equine Practice* **3** (2): 148-163.
  23. Falanga V. (2005). Wound Healing. American Academy of Dermatology (AAD).
  24. Kuwahara R.T. and Rasberry R. 2007. [Chemical Peels](#). Emedicine.com. Accessed September 15, 2007.
  25. Romo T. and Pearson J.M. 2005. [Wound Healing, Skin](#). Emedicine.com. Accessed December 27, 2006.
  26. Lansdown A.B.G., Sampson B., and Rowe A. 2001. Experimental observations in the rat on the influence of cadmium on skin wound repair. *International Journal of Experimental Pathology*, 82(1): 35-41. PMID 11422539.
  27. Ruszczak Z. 2003. Effect of collagen matrices on dermal wound healing. *Advanced Drug Delivery Reviews*, 55(12): 1595–1611. PMID 14623403
  28. DiPietro L.A. and Burns A.L., Eds. 2003. Wound Healing: Methods and Protocols. *Methods in Molecular Medicine*. Totowa, N.J. Humana Press. Electronic book.
  29. Bartkova J., Grøn B., Dabelsteen E., and Bartek J. 2003. Cell-cycle regulatory proteins in human wound healing. *Archives of Oral Biology*, 48(2): 125-132. PMID 12642231.
  30. Mulvaney M. and Harrington A. 1994. [Chapter 7: Cutaneous trauma and its treatment](#). In, *Textbook of Military Medicine: Military Dermatology*. Office of the Surgeon General, Department of the Army. Virtual Naval Hospital Project. Accessed through web archive on September 15, 2007.
  31. Larjava H., Koivisto L., and Hakkinen L. 2002. Chapter 3: Keratinocyte

- Interactions with Fibronectin During Wound Healing. In, Heino, J. and Kahari, V.M. *Cell Invasion*. Medical Intelligence Unit ; 33. Georgetown, Tex., Austin, Tex Landes Bioscience, Inc. Electronic book.
32. Witte M.B. and Barbul A. 2002. Role of nitric oxide in wound repair. *The American Journal of Surgery*, 183(4): 406-412. [PMID 11975928](#).
  33. Son H.J. Bae H.C., Kim H.J., Lee D.H., Han D.W., and Park J.C. 2005. Effects of  $\beta$ -glucan on proliferation and migration of fibroblasts. *Current Applied Physics*, 5(5): 468-471.
  34. Falanga V. 2004. The chronic wound: impaired healing and solutions in the context of wound bed preparation. *Blood Cells, Molecules, and Diseases*, 32(1): 88-94. [PMID 14757419](#).
  35. Etscheid M., Beer N., and Dodt J. 2005. The hyaluronan-binding protease upregulates ERK1/2 and PI3K/Akt signalling pathways in fibroblasts and stimulates cell proliferation and migration. *Cellular Signalling*, 17(12): 1486–1494. [PMID 16153533](#).
  36. Bayram Y., Deveci M., Imirzalioglu N., Soysal Y., and Sengezer M. 2005. The cell based dressing with living allogenic keratinocytes in the treatment of foot ulcers: a case study. *British Journal of Plastic Surgery*, 58(7): 988-996. [PMID 16040019](#). Accessed [September 15, 2007](#).
  37. Eichler M.J. and Carlson M.A. 2005. Modeling dermal granulation tissue with the linear fibroblast-populated collagen matrix: A comparison with the round matrix model. *Journal of Dermatological Science*, 41(2): 97-108. [PMID 16226016](#). Accessed [September 15, 2007](#).
  38. Hinz B. 2005. Masters and servants of the force: The role of matrix adhesions in myofibroblast force perception and transmission. *European Journal of Cell Biology* 85(3-4): 175-181. [PMID 16546559](#). Accessed [September 15, 2007](#).
  39. Mirastschijski U., Haaksma C.J., Tomasek J.J., and Ågren M.S. 2004. Matrix metalloproteinase inhibitor GM 6001 attenuates keratinocyte migration, contraction and myofibroblast formation in skin wounds. *Experimental Cell*



- Research*, 299(2): 465-475. PMID 15350544.
40. Wikipedia, 2008.
  41. O'Leary, R., Wood, E.J., and Guillou P.J. 2002. Pathological scarring: strategic interventions. *European Journal of Surgery*, 168(10):523-534. PMID 12666691.
  42. Desmouliere, A., Chaponnier, C., and Gabbiani, G. 2005. Tissue repair, contraction, and the myofibroblast. *Wound Repair and Regeneration*, 3(1):7-12. PMID 15659031.
  43. Klein E, Smith DL, Laxminarayan R (2007). "Hospitalizations and Deaths Caused by Methicillin-Resistant *Staphylococcus aureus*, United States, 1999–2005". *Emerg Infect Dis* **13** (12): 1840–6.
  44. UK Office for National Statistics Online (February 22, 2007), "[MRSA Deaths continue to rise in 2005](#)".
  45. Liu et al., A population-based study of the incidence and molecular epidemiology of methicillin-resistant *Staphylococcus aureus* disease in San Francisco, 2004-2005. *Clin Infect Dis*. 2008 Jun 1;46(11):1637-46.
  46. Noskin GA, Rubin RJ, Schentag JJ, Kluytmans J, Hedblom EC, Smulders M, Lapetina E, Gemmen E (2005). "The Burden of *Staphylococcus aureus* Infections on Hospitals in the United States: An Analysis of the 2000 and 2001 Nationwide Inpatient Sample Database". *Arch Intern Med* **165**: 1756–1761. doi:10.1001/archinte.165.15.1756. PMID 16087824.
  47. Wyllie D, Crook D, Peto T (2006). "[Mortality after \*Staphylococcus aureus\* bacteraemia in two hospitals in Oxfordshire, 1997–2003: cohort study](#)". *BMJ* **333** (7562): 281. doi:10.1136/bmj.38834.421713.2F. PMID 16798756.
  48. "Science Daily".
  49. McCaughey B, *Unnecessary Deaths: The Human and Financial Costs of Hospital Infections* (2nd. ed.).
  50. "Symptoms". Mayo Clinic.
  51. "[MRSA Toxin Acquitted: Study Clears Suspected Key to Severe Bacterial Illness](#)". *NIH news release*. National Institute of Health (2006-11-06).
  52. Schentag JJ, Hyatt JM, Carr JR, Paladino JA, Birmingham MC, Zimmer GS, Cumbo TJ (1998). "Genesis of methicillin-resistant *Staphylococcus aureus* (MRSA), how treatment of MRSA infections has selected for vancomycin-resistant *Enterococcus faecium*, and the importance of antibiotic management

- and infection control". *Clin. Infect. Dis.* **26** (5): 1204–14. doi:10.1086/520287. PMID 9597254.
53. Janknegt R (1997). "The treatment of staphylococcal infections with special reference to pharmacokinetic, pharmacodynamic, and pharmaco-economic considerations". *Pharmacy world & science : PWS* **19** (3): 133–41. doi:10.1023/A:1008609718457. PMID 9259029.
54. Sieradzki K, Tomasz A (1997). "Inhibition of cell wall turnover and autolysis by vancomycin in a highly vancomycin-resistant mutant of *Staphylococcus aureus*". *J. Bacteriol.* **179** (8): 2557–66. PMID 9098053.
55. Schito GC (2006). "The importance of the development of antibiotic resistance in *Staphylococcus aureus*". *Clin Microbiol Infect* **12 Suppl 1**: 3–8. PMID 16445718}.
56. Mongkolrattanothai K, Boyle S, Kahana MD, Daum RS (2003). "Severe *Staphylococcus aureus* infections caused by clonally related community-associated methicillin-susceptible and methicillin-resistant isolates". *Clin. Infect. Dis.* **37** (8): 1050–8. doi:10.1086/378277. PMID 14523769.
57. Birmingham MC, Rayner CR, Meagher AK, Flavin SM, Batts DH, Schentag JJ (2003). "Linezolid for the treatment of multidrug-resistant, gram-positive infections: experience from a compassionate-use program". *Clin. Infect. Dis.* **36** (2): 159–68. doi:10.1086/345744. PMID 12522747.
58. Bayston R, Ashraf W, Smith T (2007). "Triclosan resistance in methicillin-resistant *Staphylococcus aureus* expressed as small colony variants: a novel mode of evasion of susceptibility to antiseptics". *J. Antimicrob. Chemother.* **59** (5): 848–53. doi:10.1093/jac/dkm031. PMID 17337510.
59. Wang J (May 2006). "Platensimycin is a selective FabF inhibitor with potent antibiotic properties". *Nature* (441): 358–361. PMID 16710421}.
60. Cooper BS, Medley GF, Stone SP, *et al.* (2004). "Methicillin-resistant *Staphylococcus aureus* in hospitals and the community: stealth dynamics and control catastrophes". *Proceedings of the National Academy of Sciences* **101** (27): 10223–8. doi:10.1073/pnas.0401324101. PMID 15220470.
62. Graham P, Lin S, Larson E (2006). "A U.S. population-based survey of *Staphylococcus aureus* colonization". *Ann Intern Med* **144** (5): 318–25. PMID 16520472.
63. Jernigan JA, Arnold K, Heilpern K, Kainer M, Woods C, Hughes JM (2006-05-12). "Methicillin-resistant *Staphylococcus aureus* as community pathogen". *Symposium on Community-Associated Methicillin-resistant Staphylococcus aureus (Atlanta, Georgia, USA)*. Cited in *Emerg Infect Dis*, Centers for Disease Control and Prevention. Retrieved on 2007-01-27.

66. Roy, Rustom. Ultradilute Ag-aquasols with extraordinary bactericidal properties: role of the system Ag-O-H<sub>2</sub>O. Current Science Investigation, 2007.
67. University of California Berkely, MRSA and VRE susceptible to silver sol treatments, 2007.